



PATIENT

TIMON TITARENKO

SPECIES

Feline

BREED

DSH

SEX

MN

AGE

9ms

WEIGHT

8.2

PRESENTING CLINICAL SIGNS

- COUGHING
- HISTORY OF MYCOPLASMA AND BORDETELLA
- Abnormal PE/Chem/CBC/UA Results: HEART MURMUR GRADE 2/6 RADIOGRAPH-ATELECTASIS, BRONCHIAL AND INTERSTITIAL PATTERN

ULTRASONOGRAPHIC EXAMINATION OF THE HEART

FELINE CARDIAC PARAMETERS	BODY WEIGHT	HR (BPM)	IVSd (cm)	LVIDd (cm)	LVWd (cm)	FS (%)	EF (%)
NORMAL PARAMETER	-----	150-240	0.3-0.6	1.0-2.1	0.25-0.6	35-67	80-100
PATIENT	8.2	NM	0.42	1.32	0.42	45	78
FELINE CARDIAC PARAMETERS	LA/AO M-Mode	LA/AO HEART BASE (Sisson)	LAD LA MAX 4 Chamber		LVOT VEL. (m/s)	RVOT VEL. (m/s)	IVRT (m/)
NORMAL PARAMETER	<1.5	1.6	0.7-1.7		<1.6	<1.3	40-60
PATIENT	--	1.1	1.2		--	1.1	NM

Sisson D et al. JVIM 1991; 5: 232, Jacobs et al. Am J Vet Res 1985; 46:1705

INTERPRETED BY

R. McKenzie Daniel,
DVM, DABVP
(Canine and Feline)

IMAGING PERFORMED BY

Dr Sharkawy

HOSPITAL NAME

Kew Gardens Animal
Hospital

REFERRING VET

Dr Nader

INVOICE

24307

DATE

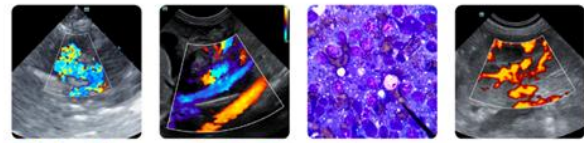
03/25/2026

Cardiac Presentation

The echocardiogram in this patient demonstrated normal left atrial size based on 3 separate LA measurements. The cranial and caudal mitral valve leaflets presented normal linear structure and kinetics. No overt MR present on Doppler. The left ventricle presented normal thicknesses with linear contour and was not dilated nor restricted. The myocardium presented normal echogenicity without subjective evidence of significant fibrotic or ischemic disease. The contractility of the ventricular walls was adequate and in normal range for this patient evidenced by the fractional shortening measurement and subjective evaluation of the different regions and angles of the myocardium. The left ventricular outflow tract demonstrated normal laminar flow and subjective structural integrity. Normal measured LVOT velocity was present. The right atrium and auricle revealed normal size, structure and content. No evidence of masses was noted or chamber overload. Tricuspid valvular assessment demonstrated adequate linear morphology and kinetics. No overt TR present on Doppler. The right ventricle was of normal size (1/3 diameter of LV), chordae structure, myocardial echogenicity and thickness. Pulmonic tract assessment revealed normal valve structure, laminar flow, and diameter (approx. 1:1 pa/ao ratio). No visible pericardial or free pleura fluid was noted or extra cardiac pathology in the visible planes. The cranial mediastinum and pericardial regions were free of masses in the visible window.

ULTRASONOGRAPHIC FINDINGS

Primary



PATIENT

- Normal cardiac structure/ function

TIMON TITARENKO

INTERPRETATION OF THE FINDINGS & FURTHER RECOMMENDATIONS

SPECIES

No evidence of structural or functional cardiomyopathy as a cardiogenic cause or contributing factor to the patient's coughing, consistent with primary lower airway disease. No indication for cardiac medications. Correlation with three view chest radiographs and respiratory support is recommended.

Feline

BREED

No anesthetic contraindications.

DSH

SEX

MN

AGE

9ms

WEIGHT

8.2

INTERPRETED BY

R. McKenzie Daniel,
DVM, DABVP
(Canine and Feline)

IMAGING PERFORMED BY

Dr Sharkawy

HOSPITAL NAME

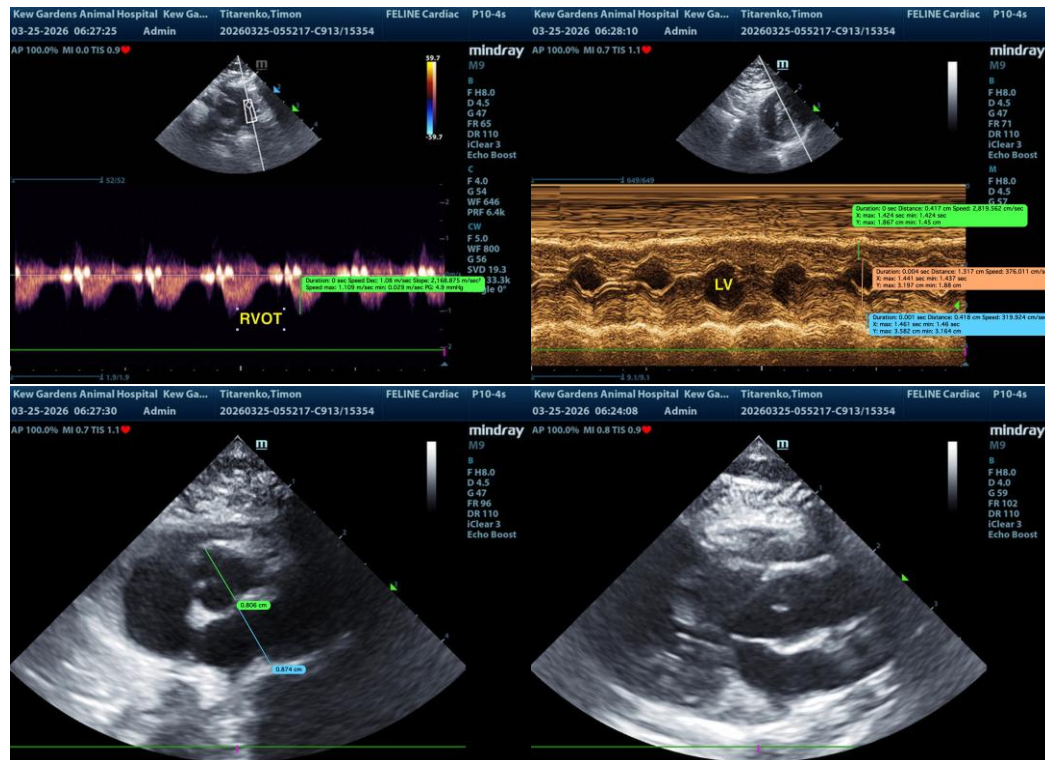
Kew Gardens Animal
Hospital

REFERRING VET

Dr Nader

INVOICE
24307

DATE
03/25/2026



The information and recommendations provided are based on the images presented by the referring veterinarian/sonographer. No evaluation can be communicated regarding pathology that was not visible in the image/video clips provided.

Thank you for this referral. If the clinical or image interpretation does not parallel your findings or if I can be of any further assistance, please contact me.

R. McKenzie Daniel, DVM, DABVP (Canine/Feline Practice)
info@sonopath.com